

Oleksii Potapov [ORCID: 0000-0002-0791-7941]

Sergii Kosiukhno [ORCID: 0000-0002-2950-9279]

Oleksandr Kalashnikov [ORCID: 0000-0002-8224-8039]

Ivan Todurov [ORCID: 0000-0001-6170-6056]

State Scientific Institution "Center for Innovative Medical Technologies
of the National Academy of Sciences of Ukraine", Kiev, Ukraine

TECHNICAL DESCRIPTION OF THE PERORAL ENDOSCOPIC DIVERTICULOSTOMY FOR THE TREATMENT OF ZENKER'S DIVERTICULUM

Corresponding author:

Oleksii Potapov

Center for Innovative Medical Technologies
of the National Academy of Sciences of Ukraine
Voznesens'kyi uzviz St., 22, 04053 Kiev, Ukraine
e-mail: potapov.md@gmail.com

Abstract

Introduction: Endoscopic treatment of Zenker's diverticulum (ZD) is one of the oldest endoscopic procedures, but has still not become the treatment of choice. Although ZD is a benign disease, it can severely impact patients' quality of life and can have serious adverse effects, such as aspiration pneumonia.

Material and Methods: Between November 2018 and February 2020 three patients (2 female, 1 male) with ZD underwent peroral endoscopic diverticulo-esophagostomy. Blood tests, ECG and tests required for general anesthesia was performed. The patients took gastrografin orally both before the procedure and 2 months afterwards.

Results: The average age of the patients was 66 years (range 54–75 years). There were no alterations in CBC, ECG and other routine tests. Upper GI endoscopy and the gastrografin test confirmed the diagnosis. All patients had stage IV ZD according to the Brombart classification. The mean operation time was 55+/-15 min. (range 40–70 min.). Blood loss was less than 20 cc. This paper gives a precise technical description of the procedure. Complete recovery was observed at the 1- and 2-month follow-ups. No complications or mortality were observed.

Conclusions: Peroral endoscopic stapled diverticulostomy is feasible and safe, even at the beginning of the learning curve. We found that the use of regular laparoscopic instrumentation along with diverticuloscope is suitable for most purposes. However, we suggest starting the endoscopic peroral program by treating carefully selected patients in centers with a developed advanced minimally invasive program.

Key words: Zenker's diverticulum, endoscopic diverticulostomy, peroral surgery, endoscopic surgery

Introduction

In our daily practice we call an esophageal pouch “Zenker's diverticulum” (ZD); this pathology was first described by Abraham Ludlow in 1769 [1]. The basic pathophysiology of the diverticulum was described in 1878 and named after German pathologist Friedrich Albert von Zenker, who along with his coauthors reported 27 cases [2].

Although ZD is a benign disease, it can severely impact patients' quality of life and can have serious adverse effects, such as aspiration pneumonia.

Despite its benign nature, according to the literature squamous cell carcinoma develops in around 0.3 to 1.5% of cases [3].

Patients present mainly with progressive dysphagia, regurgitation of undigested food, pharyngeal stasis of secretion, chronic cough and aspiration, halitosis, hoarseness, whistling and cervical borborygmi [4,5].

Some studies find even more potential complications of ZD, including pneumonia secondary to aspiration, medication ineffectiveness, malnourishment and unintentional weight loss, diverticulitis, peptic ulceration, bleeding, iatrogenic perforations during passage of endoscopes or nasogastric tubes, fistulas and vocal cord paralysis [6].

Endoscopic treatment of ZD is one of the oldest endoscopic procedures, and was described by Mosher in 1917 [7] and Dohlman and Mattsson in 1960 [8]. More recently, the works of van Overbeek and Hoeksema in 1982 [9] and Knegt et al. in 1985 have further promoted the endoscopic approach [10].

The development of fiber optics and video systems have changed endoscopic practice dramatically, but the last part of the puzzle of the minimally invasive treatment of ZD was the invention of the linear stapler. In 1993 the first cases of stapled endoscopic diverticulostomy were reported by a Belgian group lead by Collard and a British group led by Martin-Hirsch [11–13].

Material and Methods

Between November 2018 and February 2020 three patients (2 female, 1 male) with ZD underwent peroral endoscopic diverticulo-esophagostomy using a modified bladed double-action Weerda diverticuloscope (DS), Karl Storz Endoskope, Tuttlingen, Germany. The inclusion criterion was a previously diagnosed, symptomatic ZD, stage III–IV according to the Brombart classification, with no history of previous surgery of the esophagus and/or neck structures.

After the patients had been informed about possible complications (e.g. dental injuries, bleeding, perforation, mediastinitis, cardiovascular failure due to general sedation), they signed a consent form and data were collected by the participating endoscopist. Blood tests, ECG and tests required for general anesthesia were performed. Patients took gastrografin orally before the procedure (Figure 1) and 2 months afterwards.

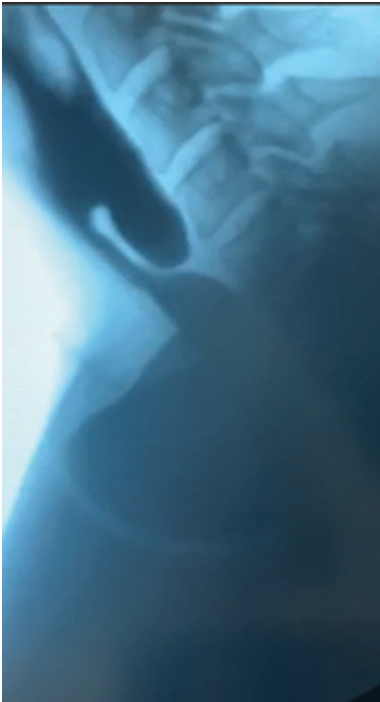


Figure 1. Oral contrast study showing clearly Zencker diverticulum.

Procedure Technical Description

The summary of the used instrumentation is listed below:

- 5 mm, 55 cm elongated 30° optics,
- HD-camera system,
- Weerda diverticuloscope (Karl Storz, Tuttlingen, Germany),

- Regular laparoscopic 5 mm Mouret grasper,
- Palpation probe,
- Suction-irrigation tube,
- Extra-long, slender clip-applying forceps for LT 200 miniclips,
- Ethicon ENDOPATH ETS-FLEX 45,
- Medtronic Endo Stitch™ Suturing Device with non-absorbable 120 cm suture,
- Laparoscopic 5 mm shears,
- Gastric boogie 14 Fr (Ch).

All procedures were performed with an endotracheal intubation according to the steps listed in Table 1. The patient was required to remove his/her prosthetic teeth, if present, and a tooth guard was positioned to protect the jaw. The “sniffing” head position with slight neck extension and head elevation are most comfortable for inserting the DS. Careful anamnesis should be performed to detect any previous neck or vertebra injury, metal implants or past surgeries in the area. A Mayo surgical table is placed above the patient’s chest, and the height of the operating table is adjusted. The DS is introduced and directed into the hypopharynx and post-cricoid region with a gently rotating movement. At this stage the camera assistant should be very careful, as elongated optics are much more fragile for the movements of the traction. Using 30° optics provides better visualization than straight-on, while an elongated optics shaft can add flexibility to the position of the camera assistant.

Table 1. Steps of the procedure

Step description	Commentary
Preparation phase	
Patient position on the operating table	
General anesthesia is induced with endotracheal intubation and the patient positioned with the head in extension	The head in “sniffing” position
Mayo surgical table is placed on the level of the patient’s chest	
Endoscopy	
Diverticulum septa, diverticulum pouch, and esophagus are identified	
Contents of the sac are cleared using suction-irrigation	Use low to middle suction power setup
Diverticulum is palpated with a soft-ended palpation probe or a Mouret grasper	Evaluation of the actual depth of the pouch

A soft bougie is placed in the esophagus leading to the stomach	We prefer to use a 14 Fr disposable nasogastric tube with the rounded end
Traction sutures placement	Endo Stitch™ with nonabsorbable suture
Employment of the Stapler	Waiting 20 seconds before and 10 seconds after firing for better hemostasis
Cutting Traction sutures	It is better to cut the sutures immediately near the tissue, to avoid sawing effect while removing the tread
Hemostasis with clips	At this stage laceration can be detected and treated endoscopically
Removing DS	

The DS is maneuvered behind the larynx and elevated to visualize the basic landmarks – the pouch, septum, and the esophageal lumen. The most negative aspect of using this technique is potential trauma while the DS is being inserted at this stage.

Then the DS is attached to the Mayo table with the Göttingen laryngoscope holder and chest support. Management of the DS blades under precise visual control allows for wide direct access to the pouch of the diverticulum and to the actual lumen of the esophagus, and allows enough space to manipulate the telescope and suction tube with the stapler.

The DS should be positioned with the open blades just proximal to both esophageal and diverticular openings, as deepening may cause mucosa injury and does not provide additional benefits for visualization.

After this step, excess food remnants should be removed with a suction irrigation tool. There are several reasons for this step – better visualization of the pouch and septa for stapling and prevention of neck contamination in the case of microperforation.

The pouch depth should be measured with a probe or laparoscopic grasper to confirm the appropriate depth for the stapler placement.

We usually examine the esophagus opening with a probe or soft boogie to be sure of the anatomy and position of the DS. The next step is to place two traction sutures in the lateral aspects of the diverticulum septa, which can provide gentle traction for the correct position of the diverticulum wall inside the stapler jaws. We prefer to put the stitch in a “up-to-down” manner.

A stapler with a blue or white vascular cartridge is then employed depending on the thickness of the wall. In our own practice we use Ethicon ENDOPATH ETS-FLEX 45 in most cases. In some cases, two loads may be required. In order to maintain visual control of the field we prefer to use two separate stapler loads rather than grab as much tissue as possible with just one load. Afterwards the stapler deployment sutures are gently pulled by the camera assistant. Damage to the mucosa should be avoided during this step. A good straight “V”-shaped incision

should be visualized at this stage. Residual millimeters should remain intact, as additional incisions beyond the staple line can potentially increase the possibility of salivary leakage from the diverticulostomy site (Figure 2).

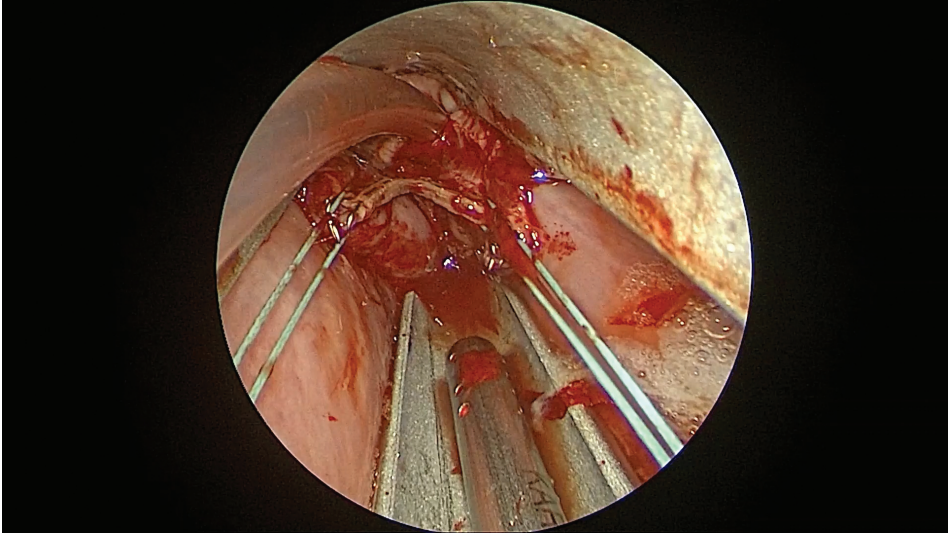


Figure 2. Intraoperative view after stapled anastomosis. Staple line can be seen in the centre of the image.

After the septa division has been finished, it is important to examine the pouch to ensure that there is no laceration. This is potentially the most serious complication and can be caused while positioning the laryngoscope or diverticuloscope, or, more commonly, positioning the stapler. In experienced hands this complication appears in fewer than 3% of patients [14]. The laceration can be repaired endoscopically if it can be visualized. We found that the 5 mm laparoscopic needle holder is stronger, offers much better control and holds the needle better than the fine “laryngeal” forceps.

Results

Preoperative evaluation:

- the average age of the patients was 66 years (range 54–75 years);
- no alterations in CBC, ECG and other routine tests;
- upper GI endoscopy and gastrograffin confirms ZD;
- all patients have stage IV ZD according to the Brombart classification;
- it takes 10 min. to position the patient’s head after general anesthesia induction;
- mean operation time was 55+/-15 min. (range 40–70 min.);
- blood loss was less than 20 cc.

Postoperative care:

- pain control with nonopioid painkillers;
- no patients had postoperative fevers or developed major complications;
- liquid diet was started on p.o. day 1;
- nasogastric tube was removed on p.o. day 3 and patients were discharged at po day 4;
- complete recovery was observed at 1- and 2-month follow-ups;
- no complications or mortality were observed.

Discussion

Classical surgical approach

The classical surgical treatment of ZD is considered to be open diverticulectomy. In most cases this procedure allows food to pass easily with continued regression of the clinical symptoms of the disease [15].

Some authors advocate adding cricopharyngeal myotomy as a prophylactic measure against ZD recurrence [16,17].

In most cases the left-sided transcervical approach is used under general anesthesia with complete muscle relaxation. 5 to 7 cm long skin incisions with subcutaneous tissue are made in the projection of the anterior edge of the left sternocleidomastoid muscle, with the omohyoid muscle identified and divided. After sharp dissection of the fascia, the left lobe of the thyroid gland is mobilized with a medial traction, while the neurovascular bundle is mobilized laterally. While being guided by a probe palpated in the region of the left posterolateral wall of the esophagus, the location of the diverticular sac is determined. The ZD pouch is then divided from the pharynx and esophagus by blunt dissection.

After the myotomy, the method for completing the procedure is selected on the basis of the size of the diverticulum and the general condition of the patient. If the diverticulum is larger than 5–6 cm then a diverticulectomy is usually performed using a linear or endo-stapler with a blue cartridge. On the other hand, invagination or diverticulopexy may be performed in cases of small diverticulum. An isolated myotomy can be performed at the initial stages of the disease. Open surgical intervention requires a precise technique, which is intended to prevent damage to the recurrent laryngeal nerve and external laryngeal nerve. Serious complications may include aspiration pneumonia, mediastinitis, perforation of the esophagus, mediastinal emphysema, pharyngeal fistula, pharyngeal abscess, esophageal stricture, wound infections, hematoma, paralysis of the vocal cords, and paralysis of the recurrent laryngeal nerve [18–20].

Modern endoscopic surgical techniques

Endoscopic diverticulostomy using a carbon dioxide laser was first proposed in 1981 by van Overbeek. This technique allows the diverticulum septa to be divided in a stapleless and bloodless manner. This method is more suitable for a small to medium-sized diverticulum. A carbon dioxide laser has high level of energy and a precisely focused beam, which provides a huge incision force while minimizing the spread of thermal damage to the surrounding tissues. This contributes to the rapid restoration of the mucosa above the surface of the incision [21,22].

Another option which can be used for ZD treatment is division of the diverticulum septa with an ultrasonic dissector. This is used in surgical practice for bloodless tissue dissection. Ultrasonic vibrations in the active part of the dissector cause increasing tissue temperature and protein denaturation due to mechanical frictional interactions, allowing the bleeding to be controlled effectively [23]. However, it is worth mentioning that ultrasonic shears can be suitable in the case of a diverticulum pouch depth of less than 2 cm [24].

The use of a flexible endoscope for dissecting the cricopharyngeal muscle using instruments introduced through the endoscope channel significantly reduces the invasiveness of the intervention. There are several positions for the flexible endoscopic peroral treatment – on the back and on the side, depending on the equipment used and preferences of the endoscope operator. It is recommended to use a cup and special disposable flexible diverticuloscope in order to visualize the cricopharyngeal muscle better. After the flexible diverticuloscope has been deployed correctly the diverticulum septum is fixed in the center of the device's lumen and provides stable access to the dissected tissues [25,26]. The choice of an endoscopic instrument for performing cricopharyngeal myotomy remains controversial and is largely determined by the personal experience and the preferences of the operating surgeon. It can be single channel endoscopic knives, Clutch Cutter scissors (Fujifilm Europe), or even an argon plasma cutter. Endoscopic clips can be used for the final hemostasis and to prevent salivary leak [24–26].

The aim of the surgical treatment is to obtain 1 cm or less of residual pouch. Incomplete cricopharyngeal myotomy can definitely cause relapse. Some authors describe the possibility of a two-stage approach. This method can potentially minimize the risk of complications [24].

Endoscopic diverticuloesophagostomy almost always allows one to resume enteral nutrition 24 hours after the procedure and to discharge at 48 hours.

As far as we know from the literature, for all existing techniques the results and complications rate are competitive [5].

One of the key aspects of the effect of the endoscopic procedure is the completeness of the intersection of the septa to the bottom of the diverticulum. However, this same circumstance becomes the main factor that can cause serious adverse events to develop, such as salivary leaks and mediastinitis. Finding

an *aurea mediocritas* between the desire to finish the procedure in one step, keep it safe and prevent complications is a rather complicated problem, and there are no clear solutions to this issue.

In some cases not only the operative technique can predict the results, but also the anatomical factors of the patient such as the individual structure of the diverticulum (wide and deep diverticulum) and its relationship with the esophagus (semi-lateral or lateral location) [5,24–26].

Some groups advocate making the decision on the type of approach on the basis of the ability to visualize the ZD and septa endoscopically, the patient's body habitus, support of the ZD pouch against the posterior wall, and local expertise [20].

Overall the low quality of the data available today does not allow a definite conclusion regarding the optimal treatment of esophageal diverticula, which seems to be a multivariate problem. Some authors advocate that partly paramedical factors such as the preferences of the doctor, the wishes of the patients, the general condition of the patient, or the availability of the minimally invasive program in the hospital should be taken into consideration when choosing a treatment method.

In our group we found that the rigid endoscopy technique is the most suitable one considering the price of the tools, the similarity of the necessary skills to laparoscopic techniques, and the overall standardization of the procedure.

Conclusions

Peroral endoscopic staple diverticulostomy is feasible and safe even at the beginning of the learning curve.

We found that the use of regular laparoscopic instrumentation along with a diverticuloscope is suitable for most purposes. However, we suggest starting the endoscopic peroral program by treating carefully selected patients in centers with a developed advanced minimally invasive program.

References

1. Ludlow A. *A case of obstructed deglutition from a preternatural dilatation of and bag formed in the pharynx.* [In:] Society of Physicians of London. *Medical Observations and Inquiries.* 2nd ed. London 1769; 3: 85–101.
2. Zenker FA, von Ziemssen H. *Dilatations of the esophagus.* [In:] Von Ziemssen H (ed.). *Cyclopedia of the Practice of Medicine.* New York, William Wood and Company, 1878; 8: 46–48.
3. Herbella FAM, Dubecz A, Patti MG. *Esophageal diverticula and cancer.* *Dis Esophagus.* 2012; 25(2): 153–158. doi: 10.1111/j.1442-2050.2011.01226.x.

4. Siddiq MA, Sood S, Strachan D. *Pharyngeal pouch (Zenker's diverticulum)*. Postgrad Med J. 2001; 77(910): 506–511. doi: 10.1136/pmj.77.910.506.
5. Bizzotto A, Iacopini F, Landi R, Costamagna G. *Zenker's diverticulum: exploring treatment options*. Acta Otorhinolaryngol Ital. 2013; 33(4): 219–229.
6. Ferreira LEVVC, Simmons DT, Baron TH. *Zenker's diverticula: pathophysiology, clinical presentation, and flexible endoscopic management*. Dis Esophagus. 2008; 21(1): 1–8. doi: 10.1111/j.1442-2050.2007.00795.x.
7. Mosher HP. *Webs and pouches of the esophagus, their diagnosis and treatment*. Surg Gynecol Obstet. 1917; 25: 175–187.
8. Dohlman G, Mattsson O. *The endoscopic operation for hypopharyngeal diverticula: a roentgen cinematographic study*. AMA Arch Otolaryngol. 1960; 71: 744–752. doi: 10.1001/archotol.1960.03770050004002.
9. van Overbeek JJ, Hoeksema PE. *Endoscopic treatment of the hypopharyngeal diverticulum: 211 cases*. Laryngoscope. 1982; 92(1): 88–91. doi: 10.1288/00005537-198201000-00019
10. Knegt PP, de Jong PC, van der Schans EJ. *Endoscopic treatment of the hypopharyngeal diverticulum with the CO₂ laser*. Endoscopy. 1985; 17(6): 205–206.
11. Collard JM, Otte JB, Kestens PJ. *Endoscopic stapling technique of esophagodiverticulostomy for Zenker's diverticulum*. Ann Thorac Surg. 1993; 56(3): 573–576. doi: 10.1016/0003-4975(93)90906-x.
12. Martin-Hirsch DP, Newbegin CJ. *Autosuture GIA gun: a new application in the treatment of hypopharyngeal diverticula*. J Laryngol Otol. 1993; 107(8): 723–725. doi: 10.1017/s0022215100124247.
13. Philippsen LP, Weisberger EC, Whiteman TS, Schmidt JL. *Endoscopic stapled diverticulotomy: treatment of choice for Zenker's diverticulum*. Laryngoscope. 2000; 110(8): 1283–1286. doi: 10.1097/00005537-200008000-00011.
14. Wilken R, Whited C, Scher RL. *Endoscopic staple diverticulostomy for Zenker's diverticulum: review of experience in 337 cases*. Ann Otol Rhinol Laryngol. 2015; 124(1): 21–29. doi: 10.1177/0003489414542421.
15. Payne WS. *The treatment of pharyngoesophageal diverticulum: the simple and complex*. Hepatogastroenterology. 1992; 39(2): 109–114.
16. Colombo-Benkmann M, Unruh V, Krieglstein C, Senninger N. *Cricopharyngeal myotomy in the treatment of Zenker's diverticulum*. J Am Coll Surg. 2003; 196(3): 370–378. doi: 10.1016/S1072-7515(02)01903-8.
17. Knigge MA, Thibeault SL. *Swallowing outcomes after cricopharyngeal myotomy: A systematic review*. Head Neck. 2018; 40(1): 203–212. doi:10.1002/hed.24977.
18. Bonavina L, Bona D, Abraham M, Saino G, Abate E. *Long-term results of endoscopic and open surgical approach for Zenker diverticulum*. World J Gastroenterol. 2007; 13(18): 2586–2589. doi: 10.3748/wjg.v13.i18.2586.
19. Simić A, Radovanović N, Stojakov D, Bjelović M, Kotarac M, Sabljak P, Skrobić O, Pesko P. *Surgical experience of the national institution in the treatment of Zenker's diverticula*. Acta Chir Jugosl. 2009; 56(1): 25–33. doi: 10.2298/aci0901025s.
20. Mantsopoulos K, Psychogios G, Künzel J, Zenk J, Iro H, Koch M. *Evaluation of the different transcervical approaches for Zenker diverticulum*. Otolaryngol Head Neck Surg. 2012; 146(5): 725–729. doi: 10.1177/0194599811435304.

21. Verhaegen VJO, Feuth T, van den Hoogen FJA, Marres HAM, Takes RP. *Endoscopic carbon dioxide laser diverticulostomy versus endoscopic staple-assisted diverticulostomy to treat Zenker's diverticulum*. Head Neck. 2011; 33(2): 154–159. doi: 10.1002/hed.21413.
22. Peretti G, Piazza C, Del Bon F, Cocco D, De Benedetto L, Mangili S. *Endoscopic treatment of Zenker's diverticulum by carbon dioxide laser*. Acta Otorhinolaryngol Ital. 2010; 30(1): 1–4.
23. May JT 4th, Padhya TA, McCaffrey TV. *Endoscopic repair of Zenker's diverticulum by harmonic scalpel*. Am J Otolaryngol. 2011; 32(6): 553–556. doi: 10.1016/j.amjoto.2010.11.009.
24. Hondo FY, Maluf-Filho F, Giordano-Nappi JH, Neves CZ, Cecconello I, Sakai P. *Endoscopic treatment of Zenker's diverticulum by harmonic scalpel*. Gastrointest Endosc. 2011; 74(3): 666–671. doi: 10.1016/j.gie.2011.05.007.
25. Repici A, Pagano N, Romeo F, Danese S, Arosio M, Rando G, Strangio G, Carlino A, Malesci A. *Endoscopic flexible treatment of Zenker's diverticulum: a modification of the needle-knife technique*. Endoscopy. 2010; 42(7): 532–535. doi: 10.1055/s-0029-1244163.
26. Leong SC, Wilkie MD, Webb CJ. *Endoscopic stapling of Zenker's diverticulum: establishing national baselines for auditing clinical outcomes in the United Kingdom*. Eur Arch Otorhinolaryngol. 2012; 269(8): 1877–1884. doi: 10.1007/s00405-012-1945-3.

Opis techniczny przezustnej endoskopowej resekcji uchyłka Zenkera

Streszczenie

Wprowadzenie: Endoskopowe leczenie uchyłka Zenkera (ZD) jest jedną z najstarszych procedur endoskopowych, jednak nadal nie jest leczeniem z wyboru. Chociaż ZD jest chorobą łagodną, może istotnie wpływać na jakość życia pacjentów i mieć poważne skutki uboczne, takie jak zachłystowe zapalenie płuc.

Materiał i metody: W okresie od listopada 2018 do lutego 2020 roku operowano 3 chorych (2 kobiety i 1 mężczyznę) z powodu uchyłka Zenkera z zastosowaniem techniki przezustnej resekcji endoskopowej. Wykonano badania krwi, EKG i testy wymagane do znieczulenia ogólnego. Pacjenci przyjmowali gastrografię doustnie zarówno przed zabiegiem, jak i 2 miesiące po zabiegu.

Wyniki: Wiek chorych wynosił średnio 66 lat (54–75). Nie stwierdzono odchyżeń w badaniach laboratoryjnych. Potwierdzenie rozpoznania opierało się na badaniu endoskopowym oraz teście z doustnym podaniem gastrografiny. U wszystkich chorych stwierdzono uchyłek Zenkera w stopniu IV wg. klasyfikacji Brombarta. Zabiegi operacyjne trwały średnio 55 (+/-15) minut (40–70 minut). Śródoperacyjna oceniana utrata krwi wynosiła poniżej 20ml. U wszystkich chorych stwierdzono pełny powrót do zdrowia po 1 do 2 miesięcy od zabiegu. Nie stwierdzono powikłań pooperacyjnych.

Wnioski: Przezustna endoskopowa resekcja uchyłka Zenkera jest bezpiecznym i skutecznym zabiegiem także w rękach chirurgów z ograniczonym doświadczeniem w tego

typu resekcji. Wykazano, że użycie zwykłego oprzyrządowania laparoskopowego z diwertikuloskopem jest odpowiednie do większości zastosowań. Niemniej zalecane jest, aby zabiegi przeprowadzane były u starannie wyselekcjonowanych chorych w ośrodkach posiadających doświadczenie w chirurgii minimalnie inwazyjnej.

Słowa kluczowe: uchyłek Zenkera, endoskopowa resekcja uchyłku, chirurgia przezustna, chirurgia endoskopowa