

Dagmara Kozłowska^{1,2} [ORCID: 0000-0002-8861-1978]

Jerzy W. Mitus^{1,3} [ORCID: 0000-0003-2417-6310]

1. Department of Surgical Oncology,
The Maria Skłodowska-Curie Memorial Institute of Oncology Cancer Centre, Krakow, Poland
2. Chair of Surgery, Faculty of Medicine and Health Sciences,
Andrzej Frycz Modrzewski Krakow University
3. Department of Anatomy, Jagiellonian University Medical College, Krakow, Poland

THE IMPORTANCE OF AN ABERRANT LEFT HEPATIC ARTERY (ALHA), SO-CALLED HYRTL'S ARTERY

Corresponding author:

Dagmara Kozłowska, Department of Surgical Oncology,
The Maria Skłodowska-Curie Institute – Oncology Center, Krakow,
ul. Garncarska 11, 31-115 Krakow, Poland;
Chair of Surgery, Faculty of Medicine and Health Sciences,
Andrzej Frycz Modrzewski Krakow University
e-mail: dagmara.kozlowska@live.com

Abstract

Knowledge of anatomical variants in hepatic vascular structures is obligatory in surgical practice. The purpose of this study is to describe anatomic variations in the Left Hepatic Artery (LHA). In ~60% of cases, LHA is a branch of the proper hepatic artery. The main anatomical variant is an Aberrant Left Hepatic Artery (ALHA) which stems from the Left Gastric Artery, also known as Hyrtl's artery. The proper identification of ALHA is of importance in the planning and performance of all surgical procedures in the upper abdomen.

Key words: variations of hepatic artery, ALHA, Hyrtl's artery

Introduction

Anatomical arterial variations can have important implications for clinical practice. Although relatively common, an aberrant left hepatic artery can be – especially if not recognized properly – a source of major complications in gastric, pancreatic and hepatic surgery.

The historical and anatomical importance of an aberrant left hepatic artery (ALHA)

The left hepatic artery usually forms as a branch of the proper hepatic artery, which is a continuation of the common hepatic artery, a branch of the coeliac trunk. Between 6% and 22% of the population have anatomic variation in the hepatic artery. Variations in the left hepatic artery (LHA) include an artery arising from the LGA as an additional vessel or as a sole source of arterial blood to the left liver lobe [1]. The first anatomist to notice variations in the LGA was Josef Hyrtl (1810–1894), a professor of anatomy in Prague and Vienna (Figure 1). In an 1873 publication Hyrtl reported that accessory hepatic arteries may develop from origins other than the CHA [2]. In his works, Hyrtl frequently pointed out how anatomical variations in different arteries can have clinical implications for surgeons [3]. This was not the case with the hepatic arterial supply since gastric surgery was in its very early stages [4] and liver surgery was only a futuristic dream [5]. With advances in surgery the importance of the hepatic arterial supply slowly increased, and today Hyrtl's works have achieved new heights of clinical significance.




Figure 1. Josef Hyrtl 1801–1894 (images from Wikipedia, common license)

Nowadays, according to the liver arterial anatomy classification, we can distinguish five types of anatomic variation in the hepatic artery. Table 1. defines these divisions precisely.

Table 1. Liver arterial anatomy classification (Anatomic variations in right liver living donors. Based on Varotti [1])

	Common hepatic artery	Gastroduodenal artery	Proper hepatic artery	Left hepatic artery	Right hepatic artery
Type 1	arise from celiac trunk	arise from common hepatic artery	extension of CHA after division of GA	arise from PHA	arise from PHA
Type 2a	arise from celiac trunk	arise from common hepatic artery	extension of CHA after division of GA	arise from PHA and arise from LGA as accessory vessel	arise from PHA
Type 2b	arise from celiac trunk	arise from common hepatic artery	extension of CHA after division of GA	arise from LGA as replacement vessel (only blood supply to the left liver)	arise after division of GA from celiac trunk
Type 3	arise from PHA	arise from common hepatic artery	extension of CHA after division of GA	arise from PHA	arise from SMA
Type 4	arise from celiac trunk	arise from common hepatic artery	extension of CHA after division of GA	arise from LGA	arise from SMA
Type 5	arises from SMA	arise from common hepatic artery	extension of CHA after division of GA	arise from PHA	arise from PHA

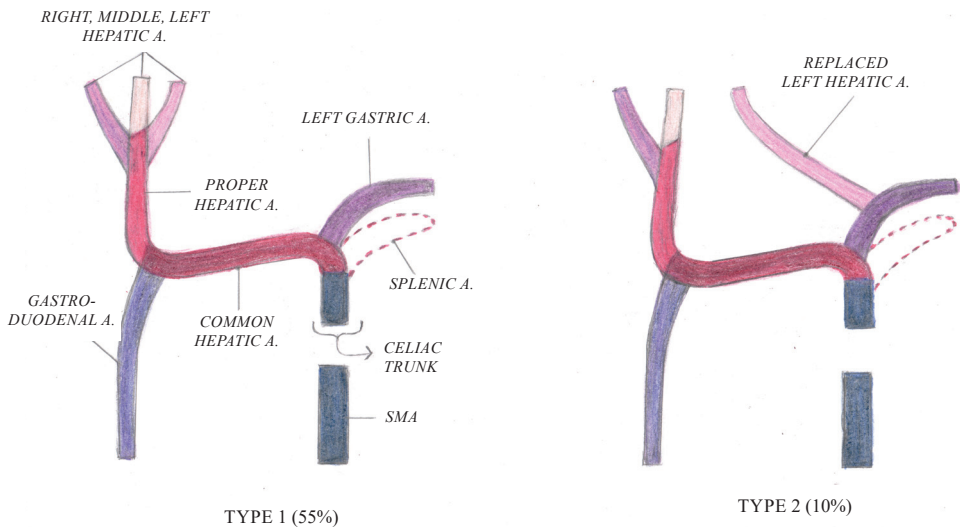


Figure 2. Type 1 and 2 variations in liver arterial anatomy

The most common variant is an aberrant left hepatic artery (ALHA) arising from the left gastric artery (LGA). An ALHA can be classified as either a replaced artery (type 2b), which is a substitute for a normal left hepatic artery, or an accessory artery, which is an addition to the normal left hepatic artery (type 2a). In a group of 1340 patients operated on for early gastric cancer there were 150 (11%) cases of ALHA [6]. In addition, data from a review study showed that the overall prevalence of ALHA is 13.52% [7]. Figure 2 shows type 1 and 2 variations in liver arterial anatomy.

Clinical importance of ALHA

Why should surgeons be aware of ALHA? In patients with ALHA, and especially in patients with chronic liver disease, we can observe postoperative complications after ALHA ligation including abscess formation, cholangitis, liver failure, and even liver lobe necrosis [6]. An ALHA arising from the LGA can be found or accidentally ligated in the hepatogastric ligament before entering the left part of the liver. The risk of damage to ALHA is highest during surgical procedures such as gastrectomy or pancreaticoduodenectomy. Surgical techniques for the preservation of the ALHA are the following: preservation of the branches of the LGA towards the lesser curvature, and closely tying the LGA away from the origin of the ALHA [8]. Most authors recommend preserving the ALHA, especially in patients with altered liver function, for example during esophagectomy [9]. However, in a study that compares ligation and preservation of the ALHA, no differences were observed between the two strategies [10]. Nevertheless, the authors emphasize that this is a retrospective study and a prospective study should be carried out. Figure 3 shows ALHA in a patient after left lateral bisegmentectomy.

With the advent of living donor liver transplantation the importance of variations in hepatic arterial anatomy and the presence of an ALHA gained new importance [11]. A detailed description of each branch of the part of the liver to be grafted is crucial to avoid complications in arterial anastomosis – one of the single most important elements of liver transplantation.

In conclusion, ALHA is a fairly common anomaly. During such surgical procedures as gastrectomy, bariatric procedures and pancreatic resections the surgeon should aim at preserving ALHA arising from an LGA diameter larger than 5 mm to prevent immediate postoperative hepatic dysfunction. Additionally, a detailed preoperative evaluation or radiological examination is needed to localize replaced arteries [6]. In patients who are candidates for donors in live donor liver transplantation a highly detailed arterial mapping of the graft is warranted [11].

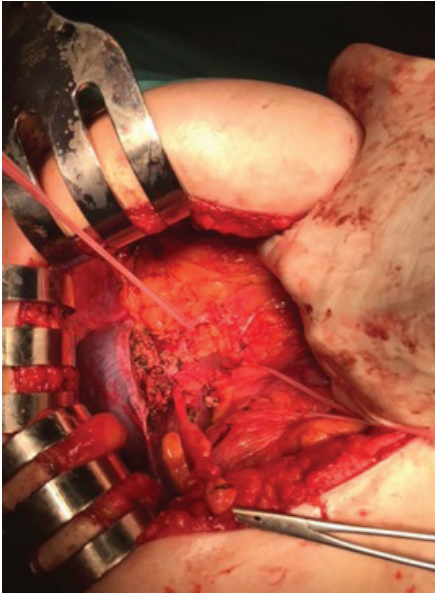


Figure 3. ALHA (on a vessel-loop) in a patient after left lateral bisegmentectomy (photo courtesy A.L. Komorowski)

Conclusion

The proper identification of ALHA is important during gastrectomy and extremely important during live donor liver transplantation.

Bibliography

1. Varotti G, Gondolesi GE, Goldman J, Wayne M, Florman SS, Schwartz ME, Miller CM, Sukru E. *Anatomic Variations in Right Liver Living Donors*. J Am Coll Surg. 2004; 198 (4): 577–582. doi: 10.1016/j.jamcollsurg.2003.11.014.
2. Hyrtl J. *Die Corrosions-Anatomie und ihre Ergebnisse*. Braumüller, Wien 1873.
3. Hyrtl J. *Varieties in the Distribution of Vessels Interesting to the Surgeon*. Prov Med Surg J. 1841; 2 (49): 464.
4. Komorowski AL, Wysocki WM, Roviello F, Marrelli D. *Gastric Resection – Bill-roth or Rydygier?*. Chir Ital. 2006; 58 (2): 231–234.
5. Komorowski AL, Lukashenko A, Chang YC. *The Past and Present of Liver Suture*. World J Surg. 2014; 38 (2): 512–518. doi: 10.1007/s00268-013-2280-6.
6. Kim J, Kim SM, Seo JE, Ha MH, An JY, Choi MG, Lee JH, Bae JM, Kim S, Jeong WK, Sohn TS. *Should an Aberrant Left Hepatic Artery Arising from the Left Gastric Artery Be Preserved during Laparoscopic Gastrectomy for Early Gastric Cancer Treatment?*. J Gastric Cancer. 2016; 16 (2): 72–77. doi: 10.5230/jgc.2016.16.2.72.

7. Cirocchi R, D'Andrea V, Amato B, Renzi C, Henry BM, Tomaszewski KA, Gioia S, Lancia M, Artico M, Randolph J. *Aberrant Left Hepatic Arteries Arising from Left Gastric Arteries and Their Clinical Importance*. *Surgeon*. 2020; 18 (2): 100–112. doi: 10.1016/j.surge.2019.06.002.
8. Shakuntala Pai R, Shahin Hunnargi A, Mamata Srinivasan. *Accessory Left Hepatic Artery Arising from Common Hepatic Artery*. *Indian J Surg*. 2008; 70 (2): 80–82. doi: 10.1007/s12262-008-0021-0.
9. Maki H, Satodate H, Satou S, Nakajima K, Nagao A, Watanabe K, Nara S, Furushima K, Harihara Y. *Clinical Evaluation of the Aberrant Left Hepatic Artery Arising from the Left Gastric Artery in Esophagectomy*. *Surg Radiol Anat*. 2018; 40 (7): 749–756. doi: 10.1007/s00276-018-2022-4.
10. Ang RRG, Lee HJ, Bae JS, Zhu CC, Berlth F, Kim TH, Park SH, Suh YS, Kong SH, Kim SH, Yang HK. *Safety of Ligation of Aberrant Left Hepatic Artery Originating from Left Gastric Artery in Laparoscopic Gastrectomy for Gastric Cancer*. *Sci Rep*. 2020; 10 (1): 5856. doi: 10.1038/s41598-020-62587-7.
11. Julka KD, Lin TS, Chen CL, Wang CC, Komorowski AL. *Reconstructing Single Hepatic Artery with Two Arterial Stumps: Biliary Complications in Pediatric Living Donor Liver Transplantation*. *Pediatr Surg Int*. 2014; 30 (1): 39–46. doi: 10.1007/s00383-013-3436-z.

Znaczenie zmienności anatomicznych lewej tętnicy wątrobowej, tzw. tętnicy Hyrtl'a

Streszczenie

Znajomość zmienności anatomicznej struktur naczyniowych jest obowiązkowym elementem w praktyce chirurgicznej. Celem artykułu jest opisanie odmian anatomicznych lewej tętnicy wątrobowej (LHA). W ok. 60% przypadków LHA to gałąź tętnicy wątrobowej właściwej. Najczęstszą zmiennością anatomiczną jest wariant lewej tętnicy wątrobowej (ALHA) odchodzącej od lewej tętnicy żołądkowej, tzw. tętnica Hyrtl'a. Prawidłowa identyfikacja ALHA jest istotna w planowaniu i przeprowadzaniu wszystkich zabiegów chirurgicznych w górnym piętrze jamy brzusznej.

Słowa kluczowe: zmienności unaczynienia tętniczego wątroby, ALHA, tętnica Hyrtl'a